Role of EUS in rectal cancer

Dr Mahsa Khodadoostan
Associate Professor of Gastroenterology and Hepatology
Isfahan University of Medical Science

- Differentiate benign and malignant rectal tumors by elastography
- Pretreatment rectal cancer staging
- Post neoadjuvant Re-staging
- Post surgical local recurrence
- EUS-FNA for suspected local tumor growth
- Fiducial marker placement

Am J Transl Res 2025;17(5):3830-3841
www.ajtr.org /ISSN:1943-8141/AJTR0161495

Review Article

Endorectal ultrasound with elastography for differentiating benign and malignant rectal tumors: a systematic review and meta-analysis

- ERUS elastography greatly enhances diagnostic precision by distinguishing rectal adenomas from cancer, providing an effective approach to differentiate benign from malignant rectal lesions.

Pretreatment rectal cancer staging

- For patients with rectal cancer, accurate pretreatment locoregional staging is necessary to select appropriate initial therapy (neoadjuvant therapy versus upfront surgery).

- the depth of transmural penetration (T stage)
- the presence or absence of suspicious perirectal nodes (N stage)
- the likely status of the circumferential resection margin (CRM)

- Locoregional tumor staging is mainly accomplished through physical examination, rigid proctoscopy , computed tomography (CT) scans, magnetic resonance imaging (MRI), and transrectal endoscopic ultrasound (TEUS).

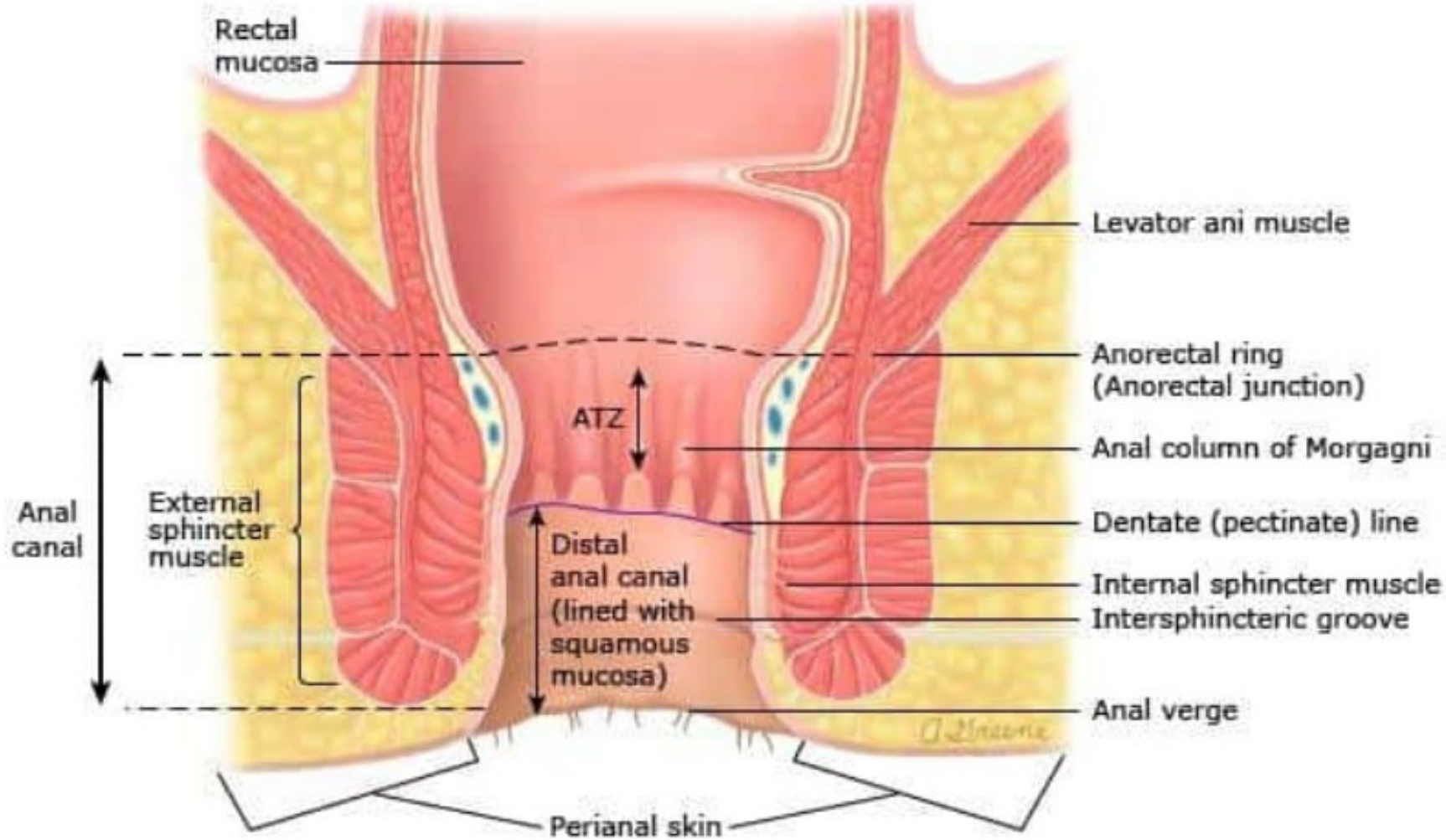
Rectal mucosa
Levator ani muscle
Anorectal ring (Anorectal junction)
ATZ
Anal column of Morgagni
Anal canal
External sphincter muscle
Dentate (pectinate) line
Distal anal canal (lined with squamous mucosa)
Internal sphincter muscle
Intersphincteric groove
Anal verge
Perianal skin

- Rigid rectoscopy is more accurate than flexible sigmoidoscopy to determine the distance between the distal tumor margin, the top of the anorectal ring, and the dentate line, as well as the orientation within the rectum (eg, anterior, posterior, left, and right)

- Accurate staging of rectal carcinoma is crucial for planning surgery and indicating adjuvant therapy.

- computed tomography and magnetic resonance imaging are very sensitive in detecting metastatic disease, the local staging of rectal cancer with these techniques has been disappointing.

- Endorectal ultrasound (ERUS) is today with Rectal MRI the most accurate methods for staging rectal and anal cancer.

Primary tumor (T)	
T category	**T criteria**
TX	Primary tumor cannot be assessed
T0	No evidence of primary tumor
Tis	Carcinoma *in situ*, intramucosal carcinoma (involvement of lamina propria with no extension through muscularis mucosae)
T1	Tumor invades the submucosa (through the muscularis mucosa but not into the muscularis propria)
T2	Tumor invades the muscularis propria
T3	Tumor invades through the muscularis propria into pericolorectal tissues
T4	Tumor invades* the visceral peritoneum or invades or adheres[¶] to adjacent organ or structure
T4a	Tumor invades* through the visceral peritoneum (including gross perforation of the bowel through tumor and continuous invasion of tumor through areas of inflammation to the surface of the visceral peritoneum)
T4b	Tumor directly invades* or adheres[¶] to adjacent organs or structures

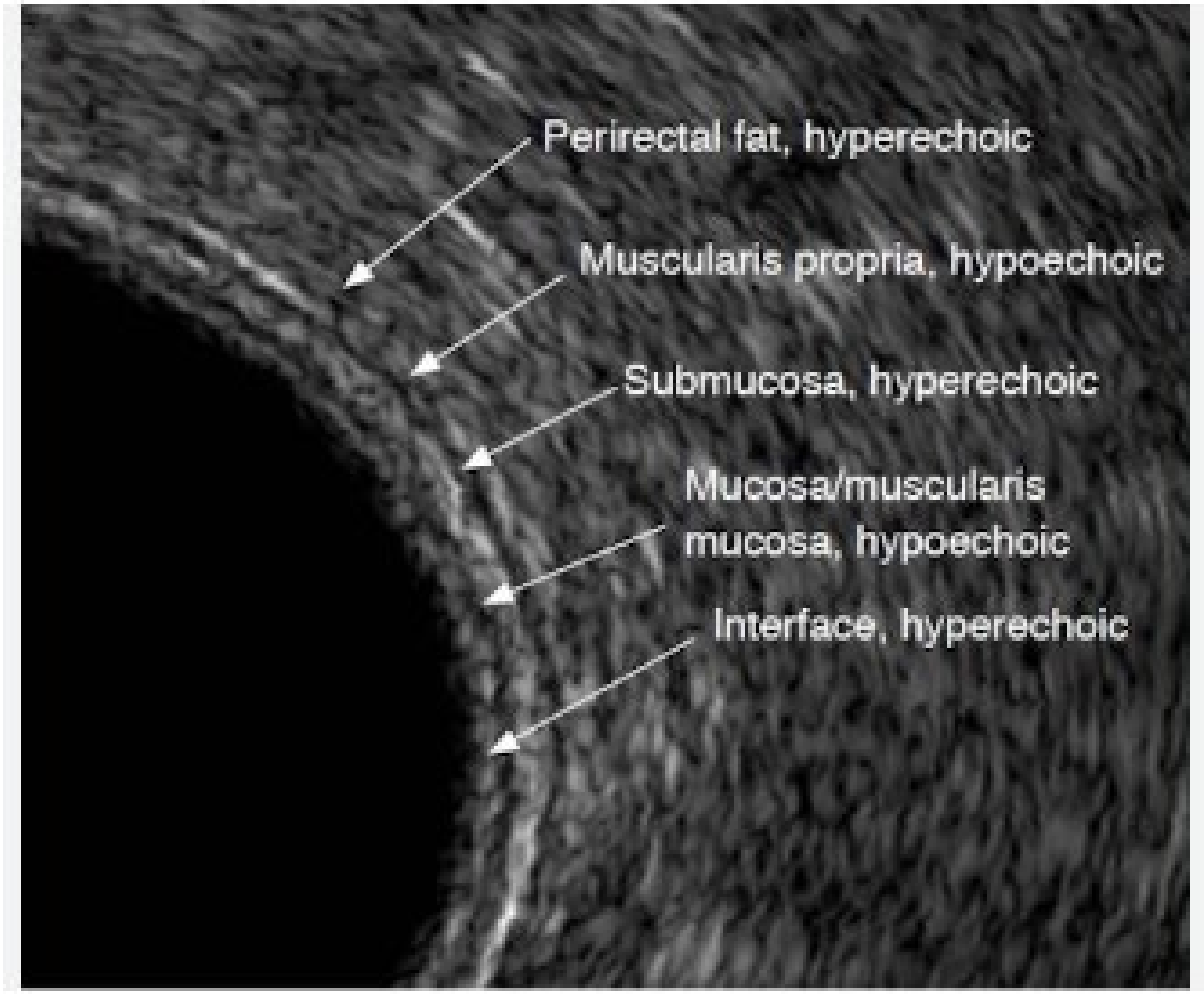
Perirectal fat, hyperechoic
Muscularis propria, hypoechoic
Submucosa, hyperechoic
Mucosa/muscularis mucosa, hypoechoic
Interface, hyperechoic

Layers of the colon and rectum with associated T stages

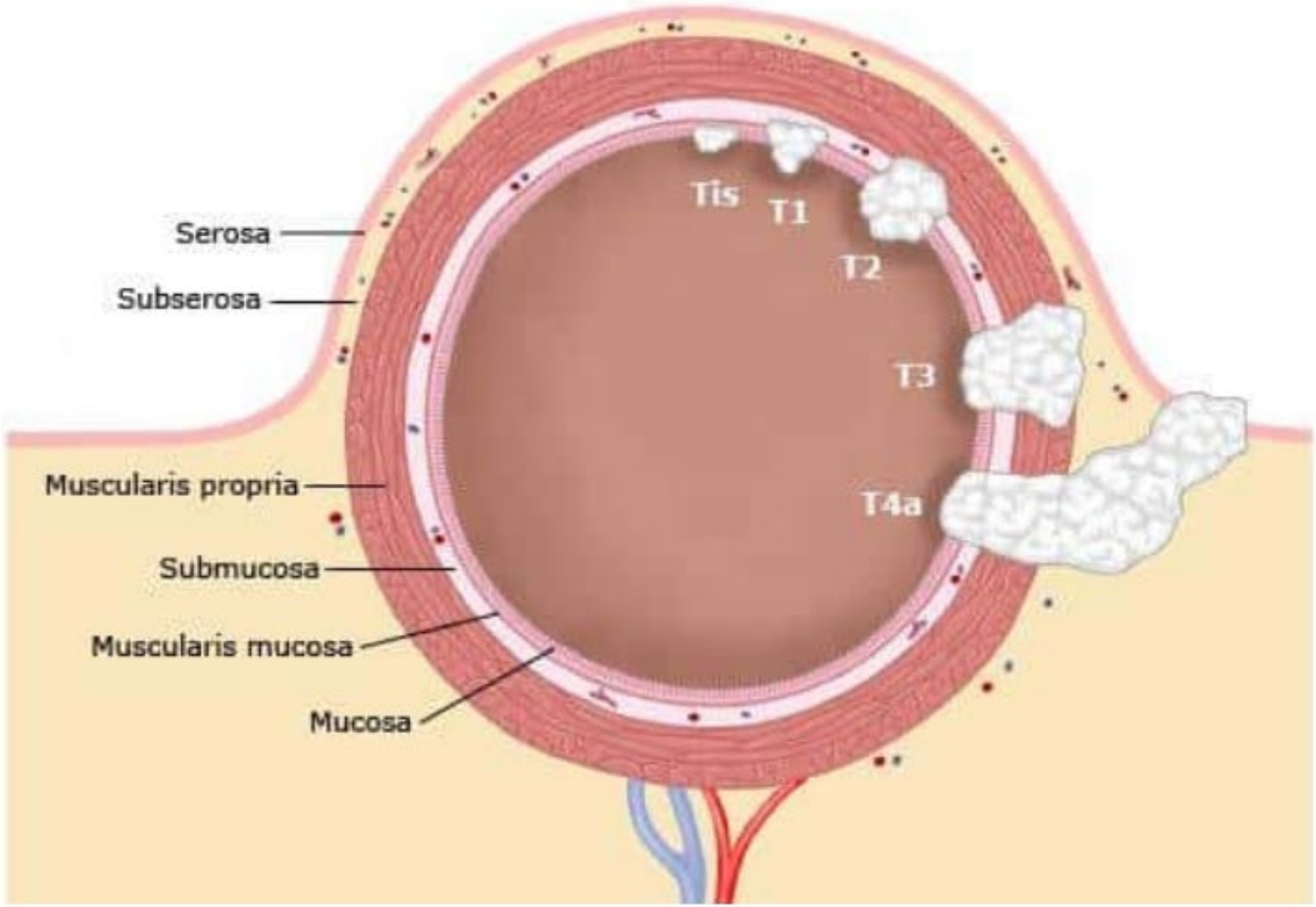

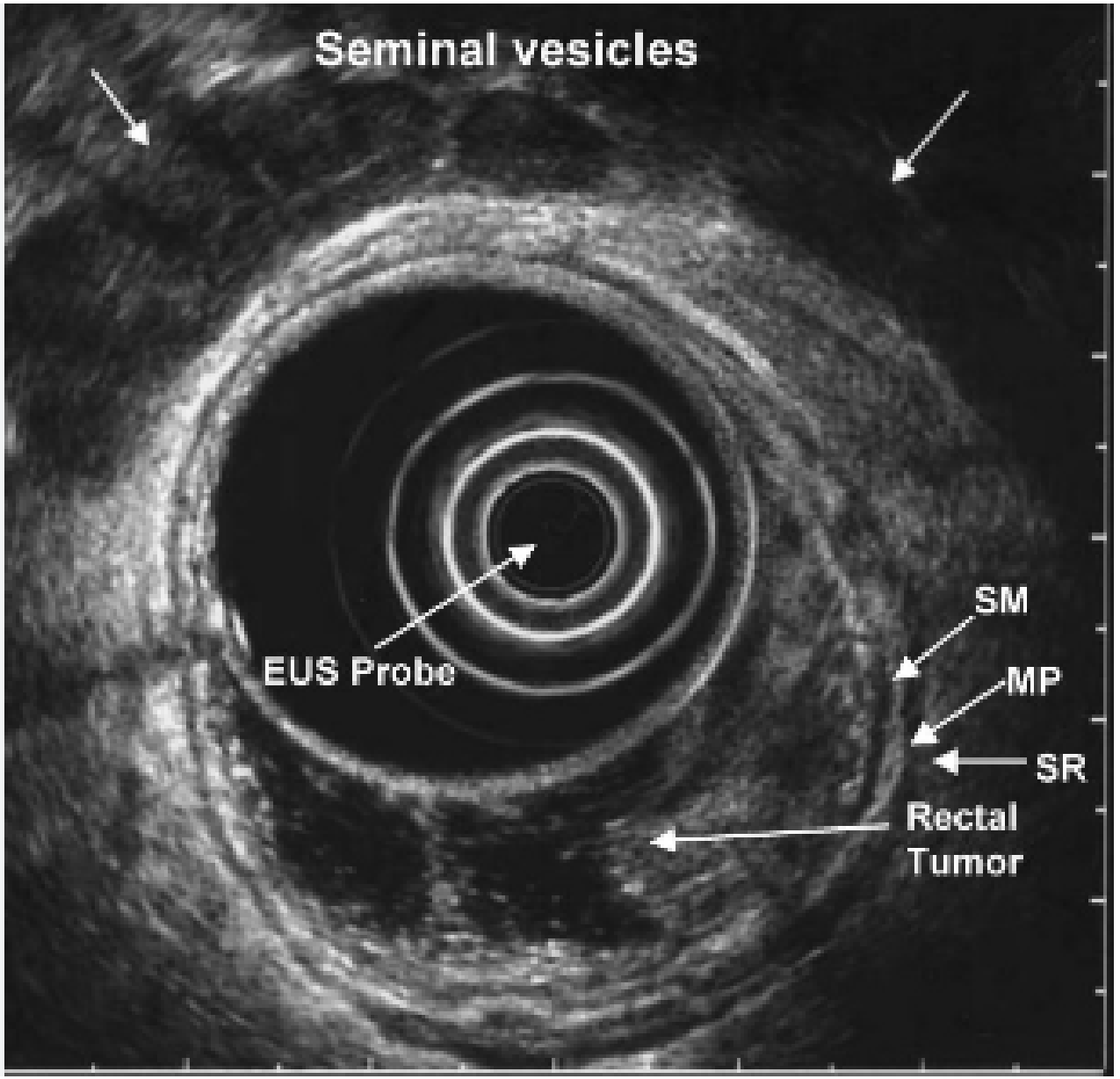
Seminal vesicles
EUS Probe
SM
MP
SR
Rectal
Tumor

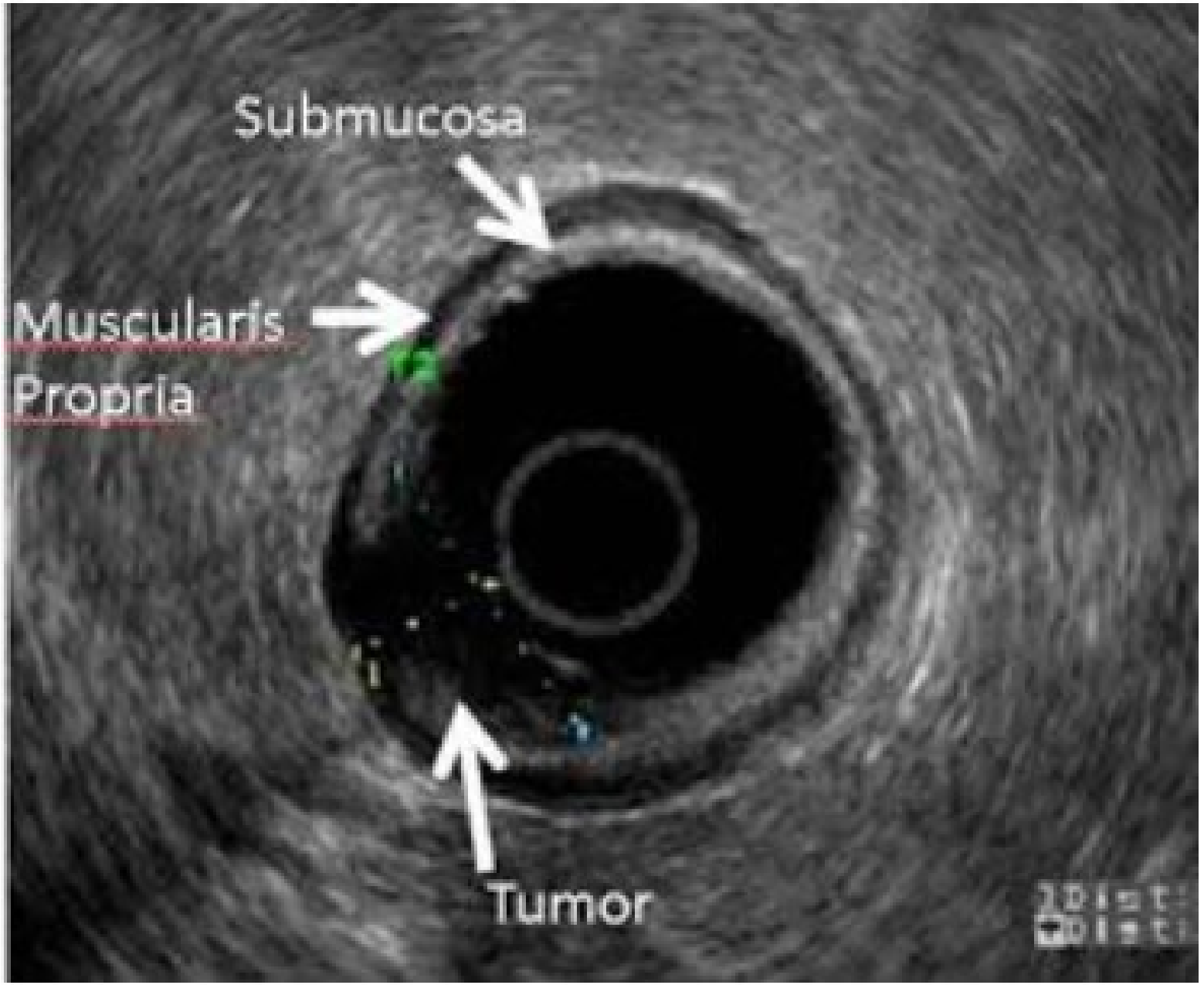
Submucosa
Muscularis
Propria
Tumor

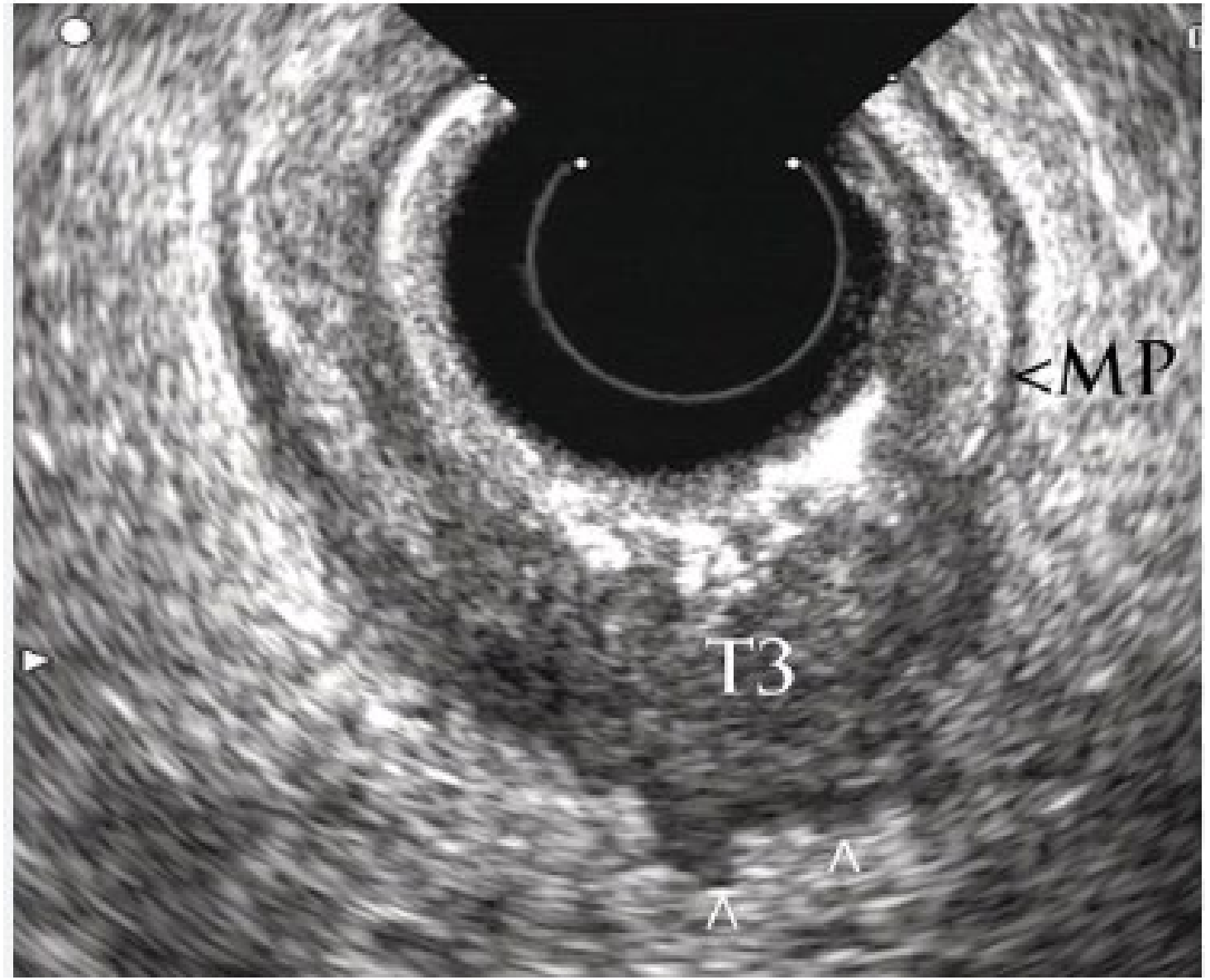
MP
T3

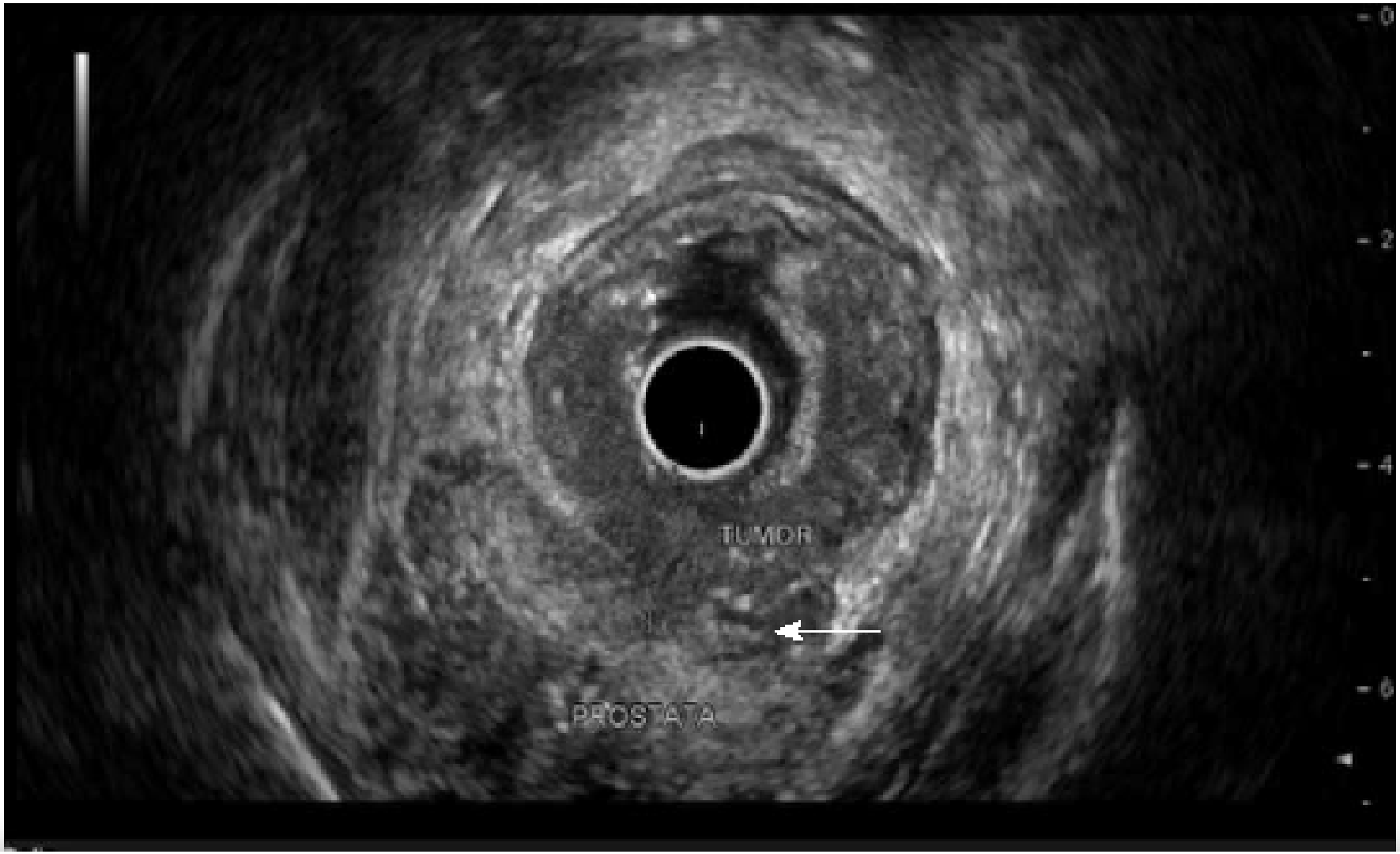
TUMOR
PROSTATA

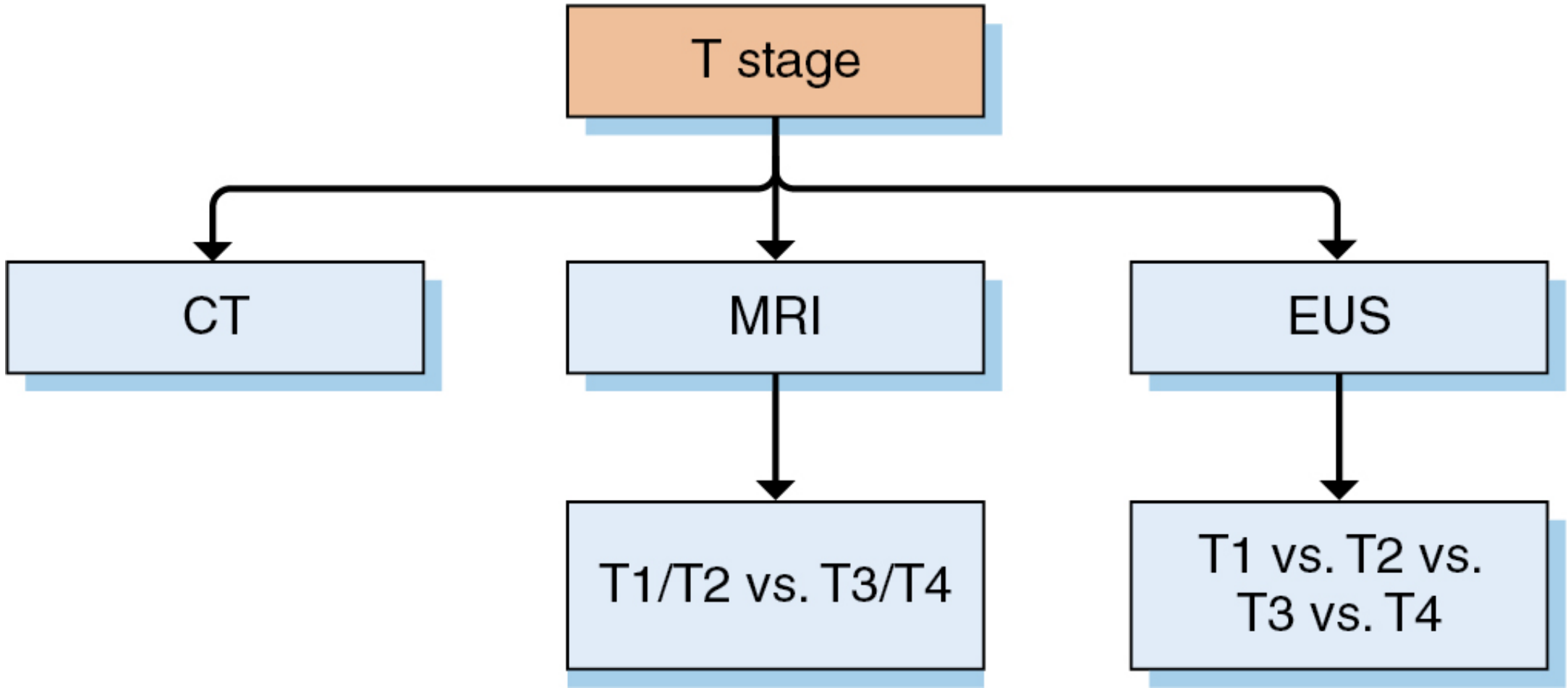
T stage
CT
MRI
EUS
T1/T2 vs. T3/T4
T1 vs. T2 vs.
T3 vs. T4

T Stage	Sensitivity (%)	Specificity (%)
T1	87.8	98.3
T2	80.5	95.6
T3	96.4	90.6
T4	95.4	98.3

Rectal cancer N stage

Regional lymph nodes (N)	
N category	**N criteria**
NX	Regional lymph nodes cannot be assessed
N0	No regional lymph node metastasis
N1	One to three regional lymph nodes are positive (tumor in lymph nodes measuring ≥0.2 mm), or any number of tumor deposits are present and all identifiable lymph nodes are negative
N1a	One regional lymph node is positive
N1b	Two or three regional lymph nodes are positive
N1c	No regional lymph nodes are positive, but there are tumor deposits in the: ▪ Subserosa ▪ Mesentery ▪ Nonperitonealized pericolic, or perirectal/mesorectal tissues
N2	Four or more regional nodes are positive
N2a	Four to six regional lymph nodes are positive
N2b	Seven or more regional lymph nodes are positive


L. Tankova, MD,PhD Sofia
RECTAL
T
T

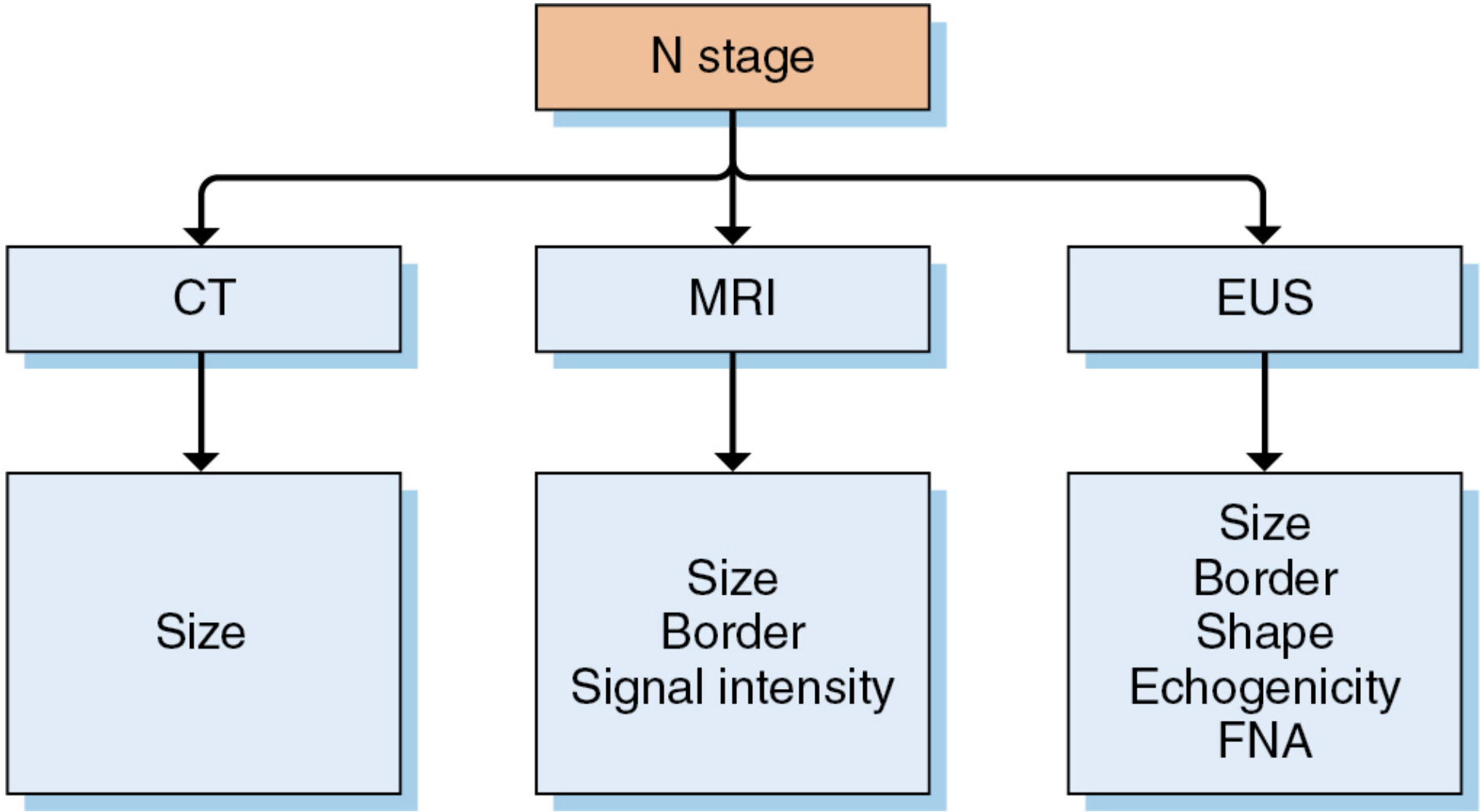
N stage
CT
MRI
EUS
Size
Size
Border
Signal intensity
Size
Border
Shape
Echogenicity
FNA

Endoscopic Ultrasonography Morphologic Features of Benign and Malignant Lymph Nodes

Endoscopic Ultrasonography Features	Benign Features	Malignant Features
Echogenicity	Hyperechoic	Hypoechoic
Shape	Irregular	Round
Border	Irregular	Smooth
Size (short axis)	<10 mm	≥10 mm

	Two or More Features	Three or More Features	Four Features
Sensitivity (%)	77	68	23
Specificity (%)	29	52	100
PPV (%)	53	60	100
NPV (%)	55	61	55
Accuracy (%)	54	61	61

- TEUS offers superior spatial resolution compared with standard CT and MRI techniques, which can provide more refined assessments of the depth of invasion for tumor staging.

- This superior resolution can be particularly useful in distinguishing T2 from early T3 tumors, which can be indistinguishable on MRI

- For patients with anterior tumors, TEUS can assess the extent of tumor involvement of the mesorectal fascia, which predicts the distance of the tumor to the circumferential resection plane after surgery

- For posterior or posterolateral tumors, the distance to the CRM can not be estimated using TEUS because the neighboring structures that allow assessment of the CRM are lacking.

- In such cases, the distance to the CRM is best estimated using MRI

- The information obtained with TEUS and MRI may be complementary and in some cases, both procedures may be needed, particularly for mid-stage tumors where there is uncertainty about T2 versus T3N0 disease or T2N0 versus N1 status.

- MRI offers some advantages over TEUS: it permits :
- a larger field of view and can visualize more proximal tumors
- it tends to be less operator and technique dependent
- it allows the study of stenotic tumors
- it can characterize lymph nodes in a wider field of view
- it can characterize perirectal lymph nodes on the basis of additional features beyond size.

Post neo-adjuvant therapy Re-staging

- Tumor response to neoadjuvant therapy is a strong predictor of disease-free survival.

- the accuracy of EUS for staging rectal cancer following such therapy is markedly decreased due to the effects of postradiation edema, inflammation, necrosis, and fibrosis.

- The T-stage accuracy following neoadjuvant therapy is 50%.

.

- the use of nonperitumoral lymph node FNA in this setting may establish the presence of residual nodal malignancy, which may offer useful information for further management decisions

EUS for recurrent rectal cancer following radical and local surgery

- important independent predictive factors for the development of local recurrence (LR):

❑positive CRM

❑serosal involvement

❑Lympho-vascular invasion

❑extramural venous invasion

❑poor histologic differentiation

- The combination of neoadjuvant therapy and TME has significantly reduced the incidence of LR (<10
- Early detection of a recurrent local tumor may result in earlier treatment and improved survival
- LR often occurs in the extraluminal region,
- EUS may not be able to visually distinguish recurrence from postoperative change due to fibrosis or inflammation, and images may be obscured by artifacts from surgically placed clips or sutures
- FNA of the residual rectal wall or perirectal space (91% sensitivity, 93% specificity)

- There is no clear strategy for the early detection of LR.

- The optimal interval for EUS surveillance following surgical intervention is unknown. However, performing EUS every 6 months for the first 2 years after low anterior resection

Fiducial marker placement

Multicenter Study > Gastrointest Endosc. 2025 Mar;101(3):570-577.
doi: 10.1016/j.gie.2024.08.014. Epub 2024 Aug 20.

Success rate of fiducial marker placement for treatment of esophageal or rectal cancers: a prospective multicenter study (FIDECHO study) (with video)

- This prospective multicenter study highlights the safety and high success of the placement of fiducial markers under EUS guidance for rectal and esophageal tumors, with no adverse events and with a short procedure time.

- Fiducial markers remained in place over time during radiation therapy

